West of England Medical Journal

Formerly Bristol Medico-Chirurgical Journal

WEMJ Volume 116 No.2 Article 3 June 2017

The e-journal of the
Bristol Medico-Chirurgical Society

Pitfalls in the early diagnosis of congenital dislocation of the hip*

Peter M. Dunn, MA, MD, FRCP, FRCOG, FRCPCH
Emeritus professor of perinatal medicine and child health, University of Bristol, UK
e-mail: P.M.Dunn@bristol.ac.uk

Congenital dislocation of the hip has been a major interest for more than fifty years during which time I have studied more than 1,500 cases. While treatment of the hips with light abduction splinting at birth is extremely effective, delayed diagnosis frequently leads to operative intervention and lifelong problems.

In this brief paper I plan to draw attention to some of the reasons for missing the early diagnosis.

EARLY DIAGNOSIS

The early diagnosis of congenital dislocation of the hip (CDH) was first proposed by Wilhelm Roser in 1879, first practiced by La Darmany in 1912, and finally publicised by Marino Ortolani in 1948[1].

Fig 1. The Ortolani test for CDH(2)

The Ortolani test (Fig 1) was designed to detect the jerk accompanying the reduction of a fully dislocated hip when the thighs of a newborn infant were abducted[2]. The problem was that the 90% of hips that were unstable but normally located in the acetabulam at rest, were overlooked. The first to appreciate this pitfall was Kurt Pálmen of Sweden who published his findings in 1961[3], followed in 1962 by Thomas Barlow of Manchester[4]. Their work led to the addition to the Ortolani test of a provocation test for hip instability, that in Britain was termed the Ortolani/Barlow manoeuvre (Fig 2).

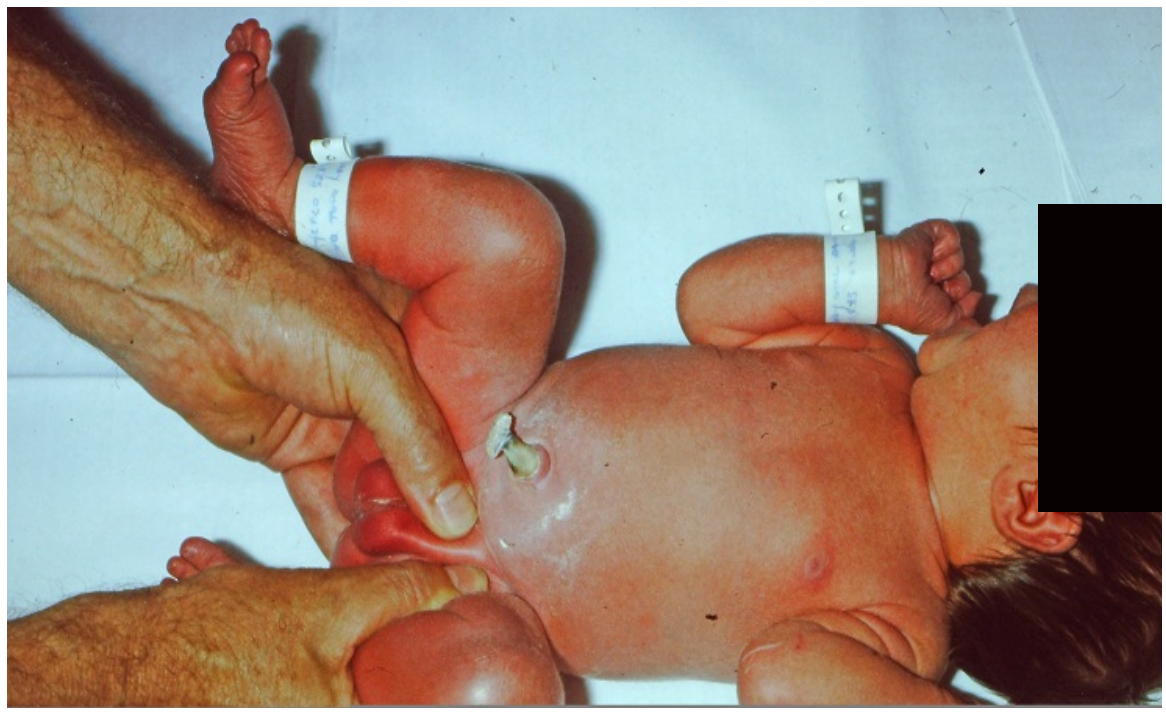

Fig 2. The Barlow/Ortolani provocation manoeuvre for detecting CDH(15).

Independently, I had also developed a provocation test for hip instability in 1960 and during the next eighteen months had referred 1% of all newborn infants born in the Birmingham Maternity Hospital to an orthopaedic clinic with a diagnosis of CDH. However all my referrals were discharged as being clinically and radiologically normal[5]. The radiologists, like the orthopaedic surgeons, had not yet grasped the significance of provoked hip instability. Fig 3a is the x-ray of one of the babies I referred at birth in 1961 to the orthopaedic clinic with an unstable left hip. It was reported as clinically and radiologically normal. Five weeks later a repeat x-ray check of the hips (Fig 3b) revealed that subluxatability had progressed to full dislocation.

Fig 3a. Hip x-ray on day 1. Unstable left hip. Referred for treatment. Reported by orthopaedic clinic as clinically and radiologically normal.

Fig 3b. Repeat hip x-ray at 6 weeks shows dislocation of left hip.

* Based on a talk to the Paediatric Visiting Club, Oporto meeting, Portugal, September 3rd, 2005

West of England Medical Journal

Formerly Bristol Medico-Chirurgical Journal

The e-journal of the
Bristol Medico-Chirurgical Society

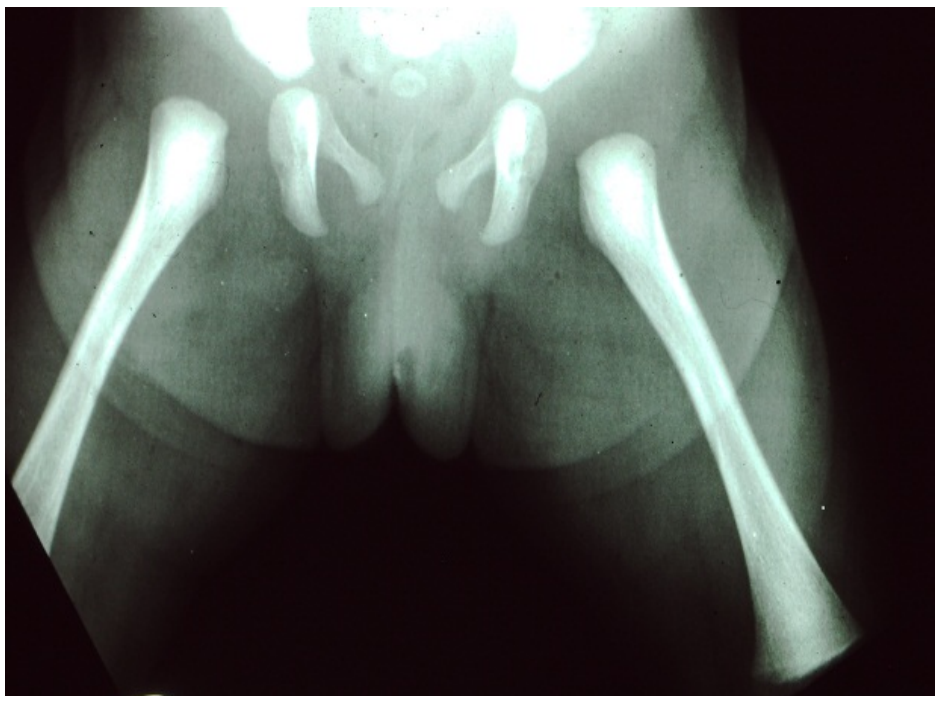

Fig 4. Provoked x-ray subluxation of right hip on day 1(6).

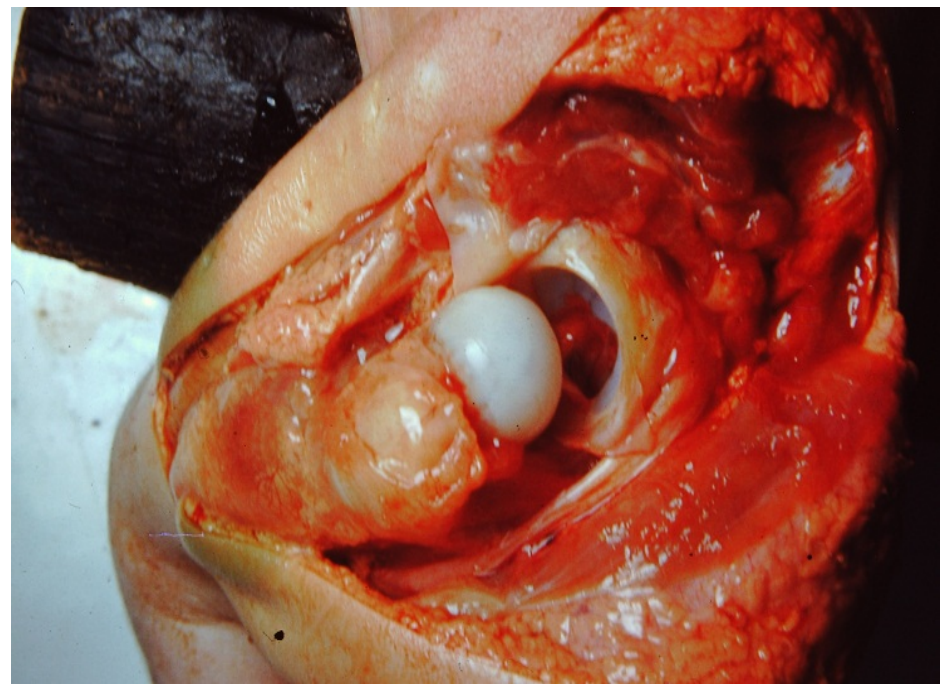

Fig 5. Post-mortem view of opened left hip joint on day 1.

In 1958 Andrén and Von Rosen of Malmo in Sweden, had published a technique for x-raying the hips in provoked subluxation[6]. I found this method very useful in persuading colleagues of the presence of hip abnormality. An example of the use of this technique in 1961 (Fig 4) shows provoked subluxation of the right hip on the second day of life.

When Rheinard Graf of Austria introduced ultrasound examination of the neonatal hip in 1980[7], a similar pitfall in diagnosis emerged. For several years Graf had recommended static ultrasound examination of the hip. However, ultrasound will often fail to detect abnormality if the hip is anatomically normal at rest (as most unstable hips are) and abnormality is only present when provoked by manipulation. As a result the great majority of sonographers now use dynamic provocation screening, though this is not easy as we have only two instead of the necessary three hands[8,9].

During the 1960s I dissected over one hundred neonatal hip-joints, half of which I had noted to be unstable or dislocated before the infant had died[10]. In a significant proportion of the unstable hips, the anatomy appeared completely normal until instability and subluxation was provoked causing the head of the femur to be displaced over the posterior rim of the acetabulum (Fig 5).

In Fig 6, may be seen two views of an unstable right hip seen from behind at post-mortem. On the left, the hip is normally located within the acetabulum, while on the right, may be seen the effect of provocation of the hip into subluxation. And to illustrate just how difficult it may be to detect the effect of provocation on the radiological appearance, Fig 7 illustrates two views of an unstable left hip (into which some radio-opaque dye has been injected) both at rest on the left, and with provocation on the right.

CLICKS AND CLUNKS

I now want to mention briefly a semantic pitfall, the difference between hip "clicks" and "clunks". This has caused a great deal of confusion over the years[11].

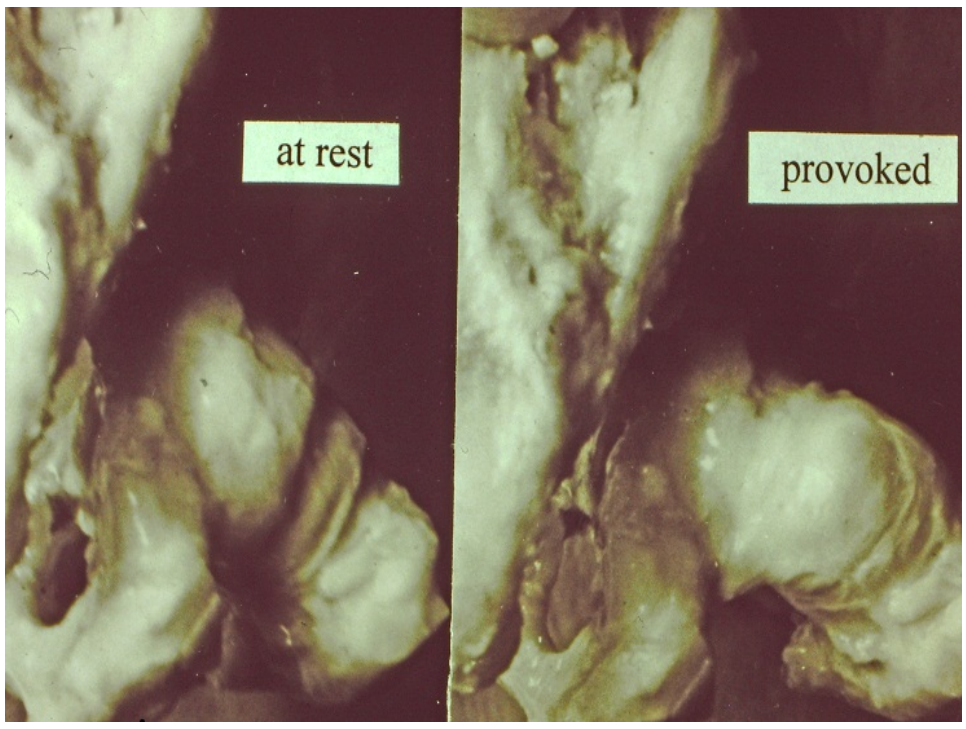

Fig 6. Post-mortem posterior views of an unstable right hip at rest and after provoked subluxation.

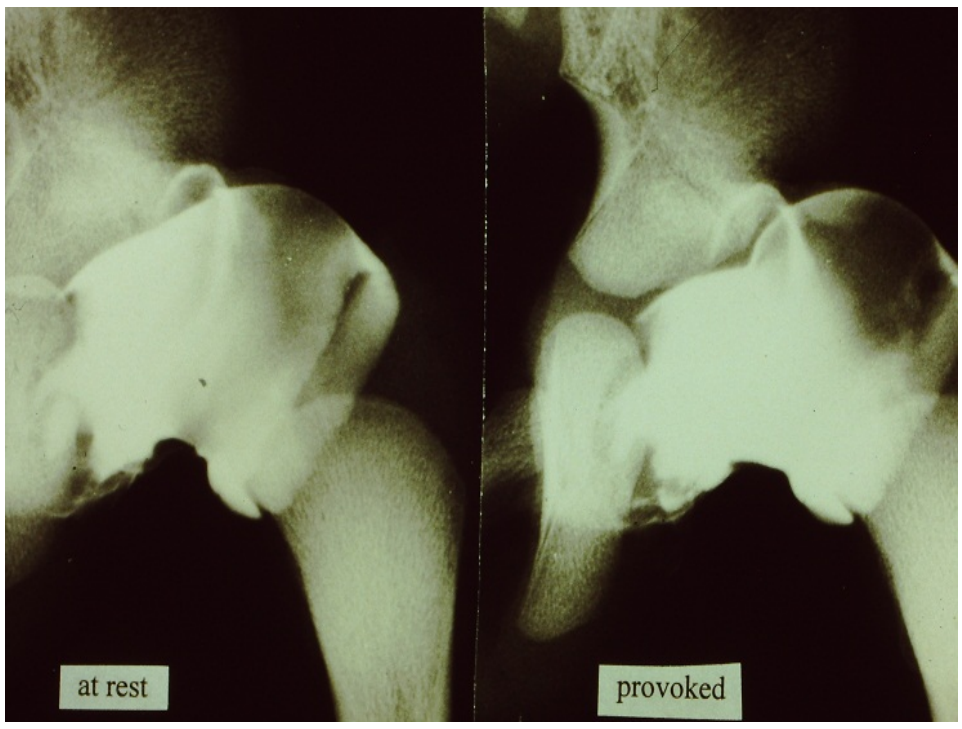

Fig 7. Post-mortem anterior views of an unstable left hip at rest and after provoked subluxation following injection of radio-opaque material.

West of England Medical Journal

Formerly Bristol Medico-Chirurgical Journal

The e-journal of the
Bristol Medico-Chirurgical Society

Fig 8. Breech-born premature infant on day 1 with unstable left hip which had stabilized by 1 week.

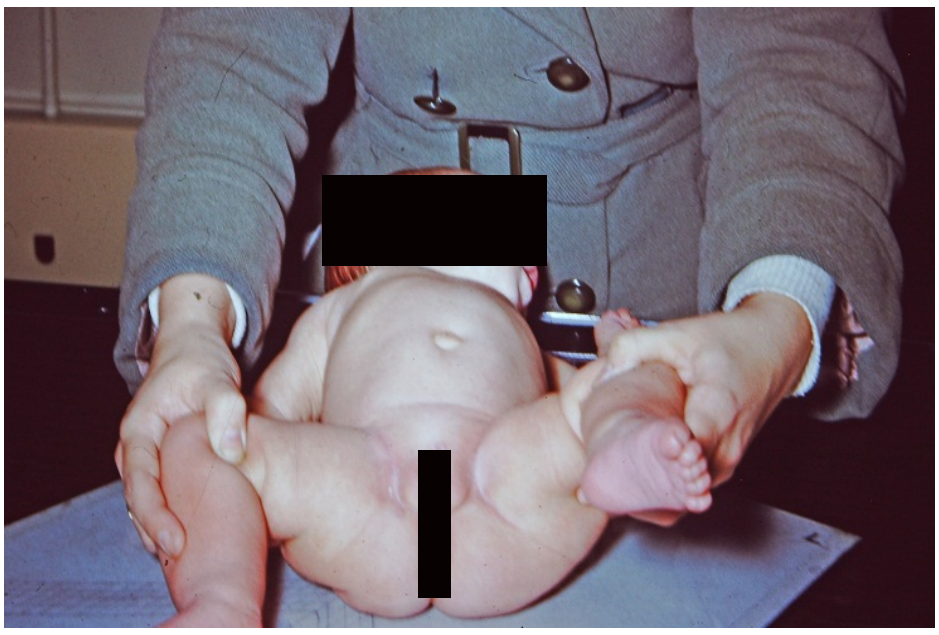

Fig 9. Same baby as in Fig 8 at age of 3 months showing limited abduction of left hip due to CDH.

With ligamentous "clicks" there is, with the Ortolani/Barlow manoeuvre, no significant movement of the femoral head out of or into the acetabulum. "Clicks" may be felt on the examination in some 5% of all babies hips. With "clunks", however, there is on provocation a movement in the order of 5mm. Over some thirty years I have never treated any infant with a clicking hip and none have ever to my knowledge later required treatment for CDH.

Among the many excellent recommendations of Thomas Barlow in the 1960s was one that, I believe, was incorrect. Namely, he claimed that once an unstable hip had stabilized it would remain stable[12]. Unfortunately I found that this was not always the case. This baby born in 1961(Fig 8) first taught me that lesson. Born by the breech, she had an unstable left hip at birth. Because of respiratory problems her hip was not treated straight away. At the age of a week when her respiratory problem had resolved, I found that her hip had stabilized. As a result I did not splint her as would have been my normal practice. However, at follow-up three months later, I found the left hip to be fully dislocated (Fig 9) and she then required orthopaedic intervention. For that reason, thereafter, all babies in my care that had unstable hips were treated at once in an abduction splint for between six to twelve weeks[13].

However I did encounter one failure and thereby hangs another pitfall. In Fig 10 may be seen the x-ray of the hips of an infant aged six months. At birth he had been diagnosed as having bilateral hip instability and was splinted in gentle abduction. In spite of two recalls he failed to attend the clinic for review and we only caught up with him at six months. As may be seen, the left hip had stabilized but the right was now fully dislocated. The story was that at the age of one week a community midwife had taken off his splint, pronounced his hips to be stable and had told his parents that there was no need for further treatment or follow-up.

Although I had no other cases like this in my care, I was able to collect thirty-five more cases of established CDH over the next twenty years that had been diagnosed by others and not splinted at birth because of early stabilization[14,15].

It was this experience that led the UK Standing Medical Advisory Committee's working party under the chairmanship of Sir Eric Stroud in 1986 to recommend strongly that all newborn infants should be examined for hip instability on day one [16]. Failure to do this was likely to give rise to many false negative examinations. You may then imagine my dismay when I read in the recent National Standard Framework for Children that newborn babies might in future receive their first examination anytime in the first week of life[17]. Some of my orthopaedic colleagues were equally dismayed.

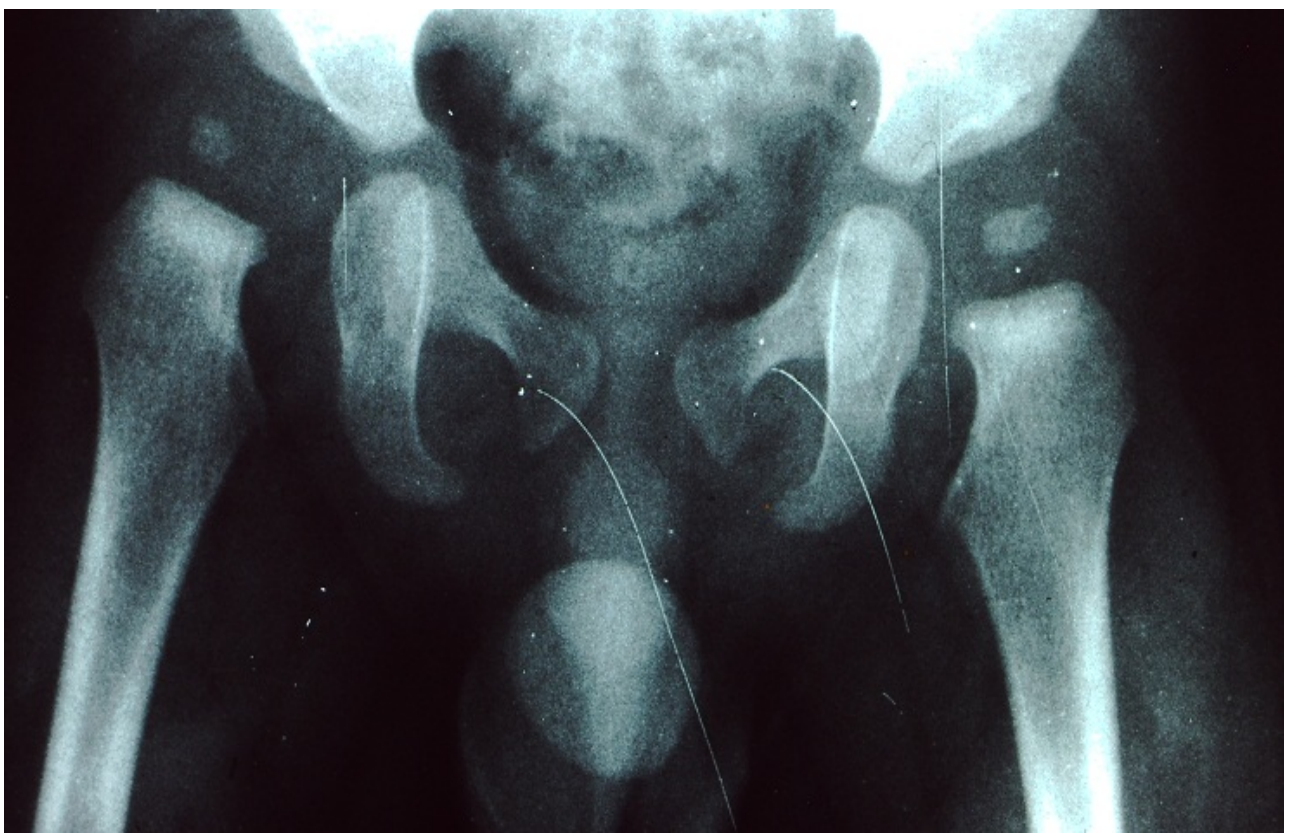

Fig 10. Infant with CDH at 6 months. Although diagnosed and splinted in abduction on day 1, treatment had been discontinued after 1 week (see text).

West of England Medical Journal

Formerly Bristol Medico-Chirurgical Journal

The e-journal of the
Bristol Medico-Chirurgical Society

Fig 11a. Left CDH at birth treated in an abduction for 3 months. Follow-up x-ray at 9 months incorrectly reported as persistent CDH.

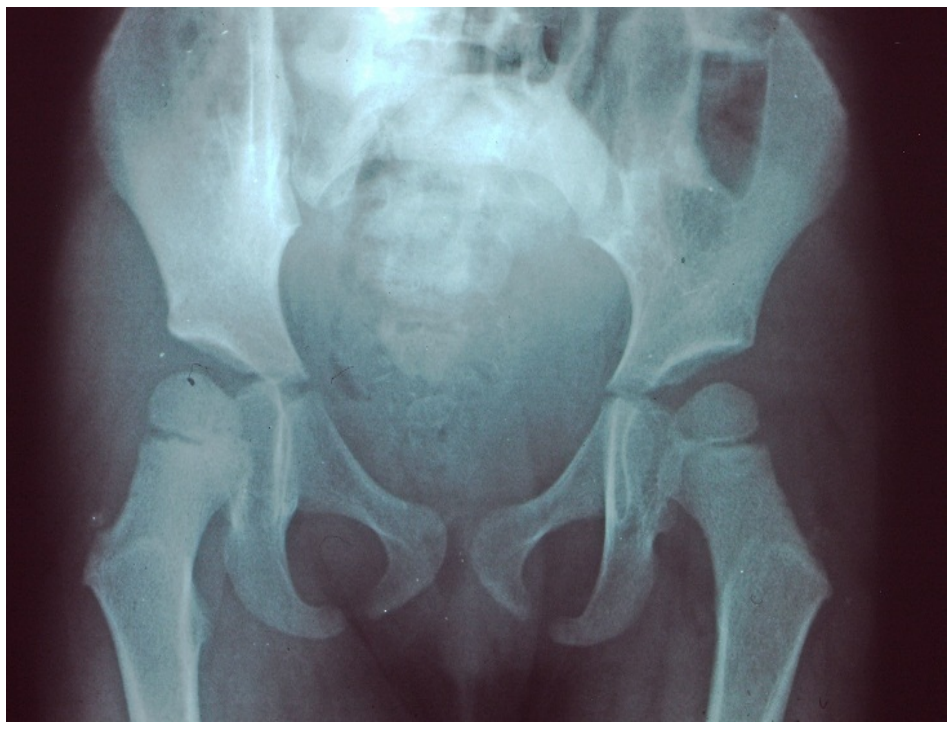

Fig 11b. X-ray hips of same baby at 3 years showing normal hip-joints (see text).

My next pitfall is a radiological one that became apparent during my follow-up of babies treated for CDH at birth in the 1970s. Here you see a follow-up x-ray at nine months of a baby born with full CDH at birth on the left side (Fig 11a).

The radiologist reported there to be a persistent CDH. However on examination the hip was clinically normal. Nor was there any upward displacement of the head of the femur in the film; and so with the agreement of my orthopaedic colleague, Mr. Peter Witherow, no further treatment undertaken.

Fig 11b shows the hip x-rays of the same child at three years with a completely normal and well-covered left hip. What we had observed in the earlier x-ray was in fact just the stigmata of a healing CDH. This is a pitfall that has led to many claims of failed early management and also to unnecessary further orthopaedic treatment of normal hips. In my collection are thirty-six similar cases seen over a fourteen-year period between 1974 and 1988(18).

My last and most important pitfall is, I regret to say, iatrogenic, namely the abysmal state of screening for CDH throughout much of the UK at the present time. Few areas can boast of an organised programme with such as that outlined in Fig 12.

As Carol Dezetreux revealed in her 1993 national survey in the UK[19], in most areas there was no co-ordinator of screening for CDH. This was often fragmented between paediatricians, sonographers and orthopaedic surgeons, while clinical screening at birth was usually delegated to junior doctors or midwives often with inadequate training and supervision. The diagnostic rate for hip instability at that time in the UK was 4 per 1000 births, perhaps 20% of the true figure which is, in my experience, around 20 per 1000.

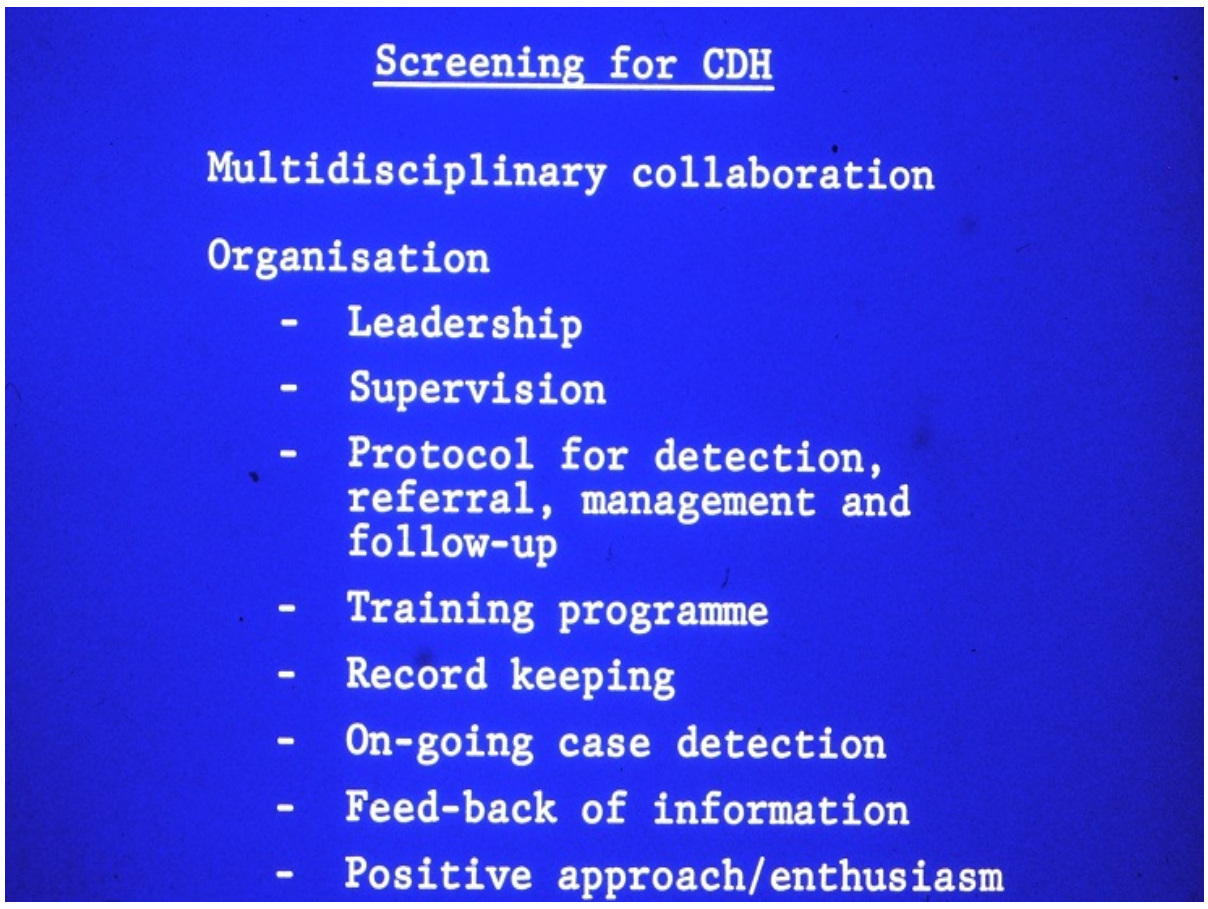

Fig 12. Organisation of area screening for CDH.

West of England Medical Journal

Formerly Bristol Medico-Chirurgical Journal

The e-journal of the
Bristol Medico-Chirurgical Society

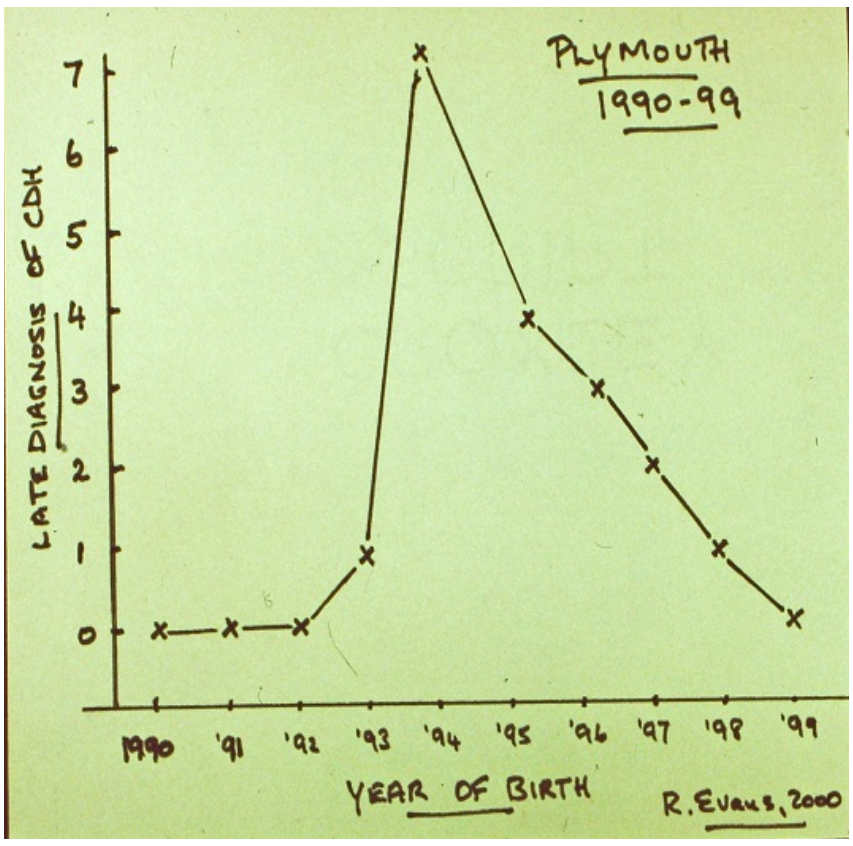

Fig 13. Late diagnosis of CDH at Derriford Hospital, Plymouth, 1990-1999. Approximately 5,000 births a year (see text).

Dr. Rosemary Evans was for many years my CDH research fellow, before appointed a consultant community paediatrician in Plymouth. After her experience in Bristol, she took a major interest in the diagnosis and follow-up of infants with CDH at Derriford Hospital in Plymouth with a birth-rate of 5000 a year.

Fig 13, based on figures which Dr. Evans kindly provided[20], shows the number of 'late' diagnosed cases of CDH at her hospital by year of birth 1990-1999 ('late' implies after the first month of life). In the first four years there was only one case missed among 20,000 births. This was followed then by a peak of no less than seven cases in 1994 among 5,000 births, followed by a steady fall over the next five years to zero cases again in 1999. What had happened at the end of 1993 and in 1994? Both the orthopaedic surgeon and paediatrician that had been supervising screening were replaced by others at that time and there was also a major change in the junior staff undertaking the screening from paediatric trainees to GP trainees. Whatever the cause, there had clearly been a major upset in the screening programme.

A CAUTIONARY TALE

Let me end with a cautionary tale. Here you see the x-ray of the hips of a woman aged thirty-five (Fig 14) with bilateral congenital dislocation of the hips and severe secondary osteoarthritis. The diagnosis of CDH had actually been made in her case in infancy but sadly she received no treatment for it at that time. Because of intolerable pain in recent years this lady had twice attempted to commit suicide. Fortunately she finally consulted an orthopaedic colleague of mine in Bristol, Mr. Harry Griffiths, and had both hip-joints replaced. Life once more became pain free and worthwhile.

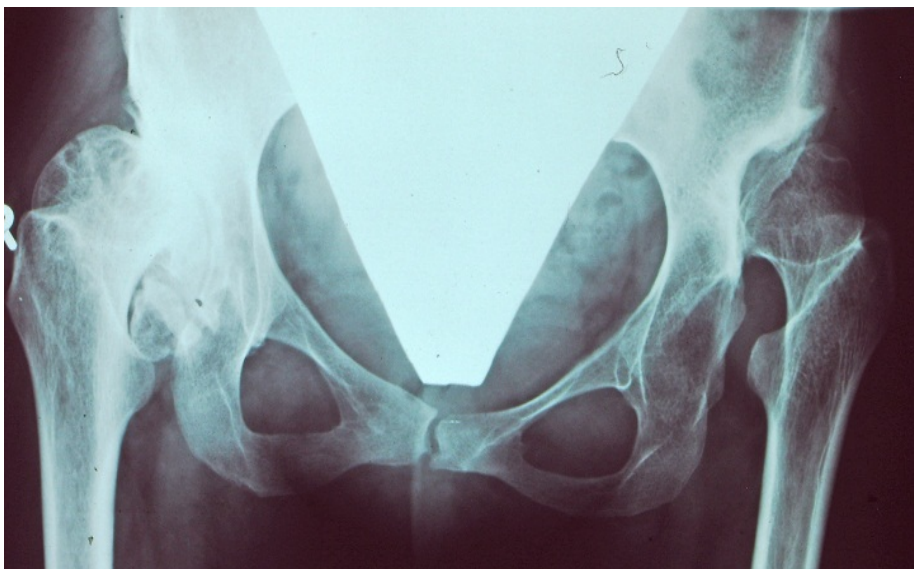

Fig 14. Bilateral CDH and severe osteoarthritis in a woman aged 35. Although the diagnosis of CDH was made at birth, no treatment was instituted (see text).

REFERENCES

1. Dunn, P.M. The history of screening for congenital dislocation of the hip. Proc. Bristol Medico-Historical Society (1999-2003), Vol IV, 2006; 147-157.
2. Ortolani, M. La Lussazione Congenila dell'anca. Nuovi criteri diagnostici e profilatico. Correttivi, Bologna: Editore Capelli, 1948.
3. Palmén. K. Preluxation of the hip joint: diagnosis and treatment in the newborn and the diagnosis of congenital dislocation of the hip joint in Sweden during the years 1945-60. Acta Paediatr Suppl (Uppsala): 1961; 50:129.
4. Barlow, T.G. Early diagnosis and treatment of congenital dislocation of the hip. J. Bone Joint Surg, 1962: 44-B: 292-301.
5. Dunn, P.M. The influence of the intrauterine environment in the causation of congenital postural deformities with specific reference to congenital dislocation of the hip. MD thesis, 3 vols., Cambridge University; 1969.
6. Andrén, L. and Rosen, S.von. The diagnosis of dislocation of the hip in newborns and the primary result of immediate treatment. Acta. Radiol. 1958; 49, 89.
7. Graf, R. The diagnosis of congenital hip joint dislocation by ultrasound compound treatment. Arch. Orthop. Trauma Surg., 1980; 97: 117.
8. Gardiner, H.M., Clarke, N.M.P. and Dunn, P.M. A sonographic study of the morphology of the preterm neonatal hip. J. Pediatr. Orthop., 10, 633-7.
9. Gardiner, H.M., Dunn, P.M. The congenitally dislocatable hip: controlled trial of immediate splinting versus ultrasonographic surveillance. Lancet, 1990: 336: 1553-6.
10. Dunn, P.M. The anatomy and pathology of congenital dislocation of the hip. Clin. Orthop., 119, 23-7.
11. Dunn, P.M. Clicking hips should be ignored. Lancet, 1984: i: 846.
12. Barlow, T.G. Congenital dislocation of the hip. Hospital Medicine, 1968; 2: 571-7.
13. Dunn, P.M., Evans, R.E., Thearle, M.J., Griffiths, H.E.D. and Witherow, P.J. Congenital dislocation of the hip: early and late diagnosis and management compared. Arch. Dis. Childh, 1985; 60: 407-14.
14. Dunn, P.M. Screening for congenital dislocation of the hip. In: Progress in Child Health, Vol 3. Ed. Macfarlane, J.A. Edinburgh: Churchill Livingstone; 1987, p.1-13.
15. Dunn, P.M. Congenital dislocation of the hip: screening, diagnosis and management. In: Care, Concern and Cure in Perinatal Medicine. Proc. XIII Europ. Congr. Perinat. Med., Amsterdam, May 1992. Ed. by Koppe, J.G. et al. Parthenon Publ. Co., Lancs., 1993, pp.297-300.
16. Standing Medical Advisory Committee and Standing Nursing and Midwifery Committee Working Party; chairman, Stroud, C.E. Screening for the detection of congenital dislocation of the hip. Arch. Dis. Childh, 1986; 61: 921-6.
17. Gray, M. (Programme Director of the UK National Screening Committee). The Times, March 27th, 2001.
18. Dunn, P.M. Congenital dislocation of the hips: A paediatric responsibility. The 1st David Baum memorial lecture. Royal College of Paediatrics & Child Health/American Academy of Pediatrics. Institute of Child Health, London, March 2nd/3rd, 2000. In: P.M. Dunn, CDH, 2000-2007, held by University of Bristol Medical Library, Bristol.
19. Dezateux, C., Godward, S. A national survey of screening for congenital dislocation of the hip. Arch. Dis. Childh., 1996; 74: 445-8.
20. Evans, R.E. Personal communication, 2000.