West of England Medical Journal

Formerly Bristol Medico-Chirurgical Journal

The e-journal of the
Bristol Medico-Chirurgical Society

Imaging of Vertebral Trauma by Richard H. Daffner

WEMJ Volume 112 No 2 Article 2 June 2013

Third Edition. Cambridge University Press 2011. pp 224.
ISBN: 978- 0521- 89701- 3. Hardback

Reviewed by Rebecca Geach
Specialisr Registrar, Radiology, Bristol

REVIEW

Injuries to the vertebral column are common particularly in the trauma setting. In the last decade there has been increasing importance placed upon rapid imaging of the spine in trauma patients and the focus has shifted from plain radiography with increased utilization of both CT and MRI.

Daffner presents the third edition of Imaging of Vertebral Trauma aimed primarily at radiologists although the book would also provide a useful reference guide for any doctor working with trauma patients.

The primary difference in this third edition from both the first (1988) and second (1996) editions is the shift in focus from plain radiography to CT in the detection of acute vertebral trauma. Current literature is referenced to provide the latest guidance on the indications and methods of imaging vertebra trauma.

Sections based upon MRI imaging have been updated to reflect changes in technology and practice and there has been the addition of a new chapter focusing solely on paediatric injuries.

There are eleven chapters in total that cover a range of topics including anatomy, normal variants and pseudofractures and biomechanical elements relating to vertebral trauma. The main imaging section is essentially divided into three chapters that are split into
1) indications,
2) radiography, computed tomography and myelography
3) magnetic resonance imaging.

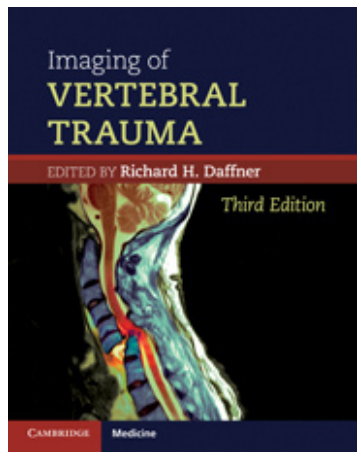

Each chapter helpfully begins with a description of relevant terminology and where appropriate an abbreviation lists relevant to that chapter. Text is divided by headings and subheadings and illustrative figures referenced within the body of the text. Figures are therefore not incorporated within the text and occasionally you have to flick through several pages to find the relevant figure referenced in the text body.

Summary tables/bullet points are provided at the end of some chapters which provided and excellent recap of salient points to remember. When appropriate findings demonstrated on plain radiography are further explained and illustrated on CT/MRI that enables pathology to be demonstrated across several modalities. In general the quality of the images is good, there are however a few plain radiographs that have poor contrast resolution and findings are difficult to appreciate in normal reading light.

Particularly within the anatomy chapter there are multiple photographs and plain radiographs all of which I did not deem necessary. It meant that the chapter was long and expanded and difficult to read in a single sitting. The inclusion of diagram illustrations did however enhance my understanding of more difficult anatomical concepts.

I found the chapter layout a little confusing. The initial chapters seemed logical dealing with the anatomical and biomechanical aspects related to vertebral trauma but the imaging sections were disjointed. Presentation of imaging indications did outline current evidence related to several utilised protocols such as the Canadian C-Spine imaging tool. The author also presented his own experience working in an American major trauma centre. However in terms of pathology: although there were chapters presenting findings in different modalities further chapters entitled 'Radiologic 'footprints' of vertebral injury: the ABCs' and 'Vertebral stability and instability' meant that several pathologies/concepts were described multiple times in different chapters. In addition figures used to illustrate these descriptions were also repeated across chapters.

The addition of the new paediatric injury (Geetika Khanna and George Y El-Khoury) was beneficial with particular reference to imaging indications in children and anatomical variants that can be confusing especially to a radiology trainee.

CONCLUSION

Although I found this book a useful reference text because of the chapter layout it is necessary to read the entire book rather than focusing on a particular chapter to fully understand the different concepts and imaging findings.

There are plenty of illustrative figures and as a radiology trainee this maintained my interest through occasional heavy descriptive text. The content of the book is excellent but my overall opinion is that it could have been presented in a more logical and succinct fashion providing an easier and more enjoyable read.