



West of England Medical Journal

Formerly Bristol Medico-Chirurgical Journal



The e-journal of the
Bristol Medico-Chirurgical Soc

FROM THE ARCHIVES OF THE JOURNAL

The New "Photography"

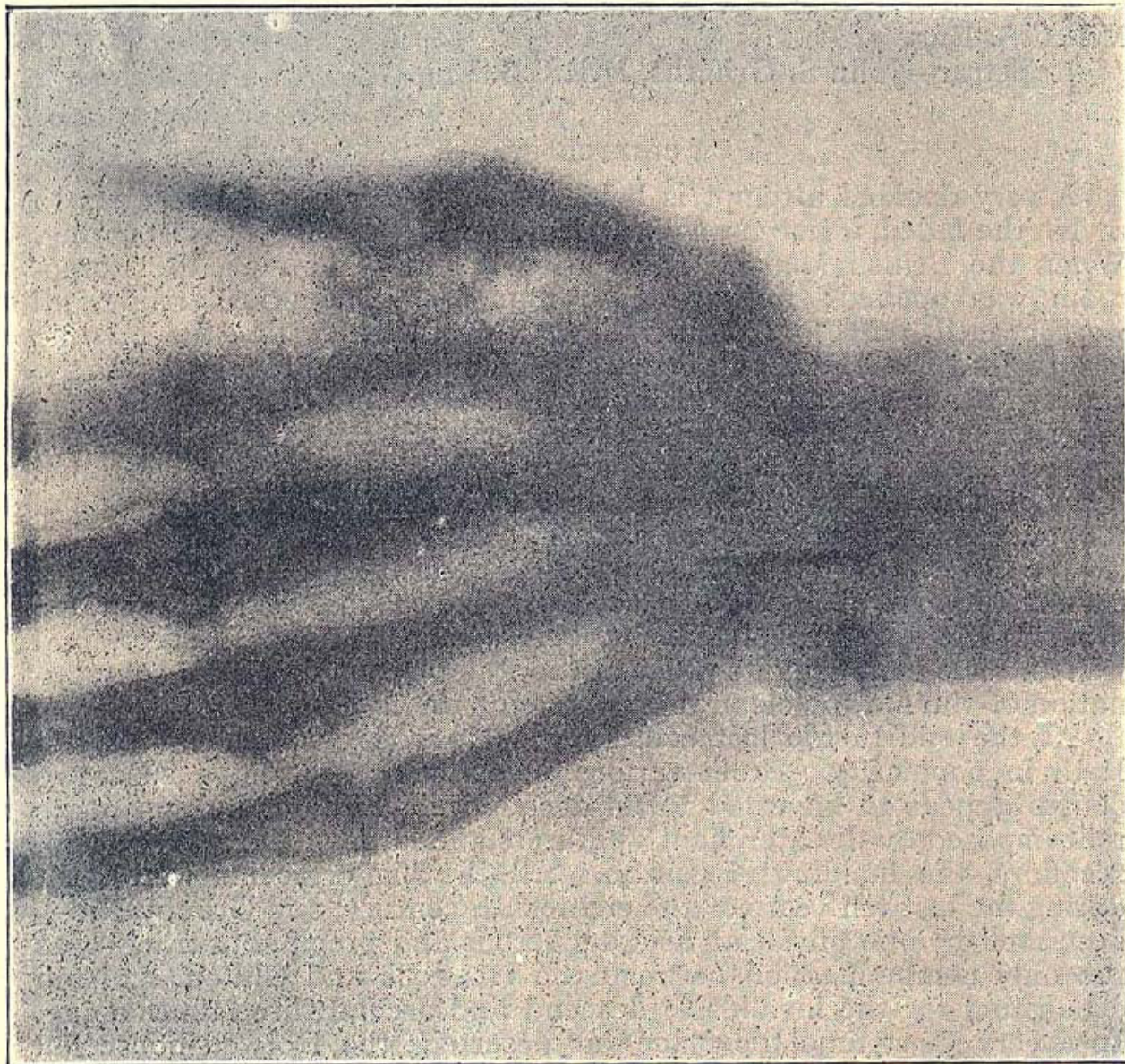
From the Bristol Medico Chirurgical Journal 1896 Page 112

Editor's note: This is an example of the very early use of X-rays just six weeks after the publication of Roentgen's first paper on his discovery.

The medical value of X-rays was extremely quickly established

THE NEW "PHOTOGRAPHY."

On February 10th Mrs. L. consulted Mr. T. F. Edgeworth on account of pain in the front of the right wrist, due, she thought, to a needle which had accidentally penetrated the skin. There was some tenderness on pressure, but nothing further could be made out. Before any exploratory incision was made, Professor Wertheimer, the Principal of the Bristol Merchant Venturers' College, very kindly made a radiogram by Röntgen's rays. It showed the needle quite distinctly.



A few days subsequently, after an injection of cocaine, the needle was easily removed. The radiogram was of great assistance in showing that the needle was there, and also its exact position, so that an incision could be made just over the upper end of it.

This is the first case in Bristol in which surgical use has been made of the discovery.