West of England Medical Journal

Formerly Bristol Medico-Chirurgical Journal

WEMJ Volume 115 No.3 Article 3 September 2016

The e-journal of the
Bristol Medico-Chirurgical Society

Congenital postural deformities of the lower limbs: a case history

Peter M. Dunn, MA, MD, FRCP, FRCOG, FRCPCH
Emeritus professor of perinatal medicine and child health, University of Bristol, UK
e-mail: P.M.Dunn@bristol.ac.uk

CASE HISTORY

The mother, a primigravid woman, aged twenty-eight, had a history of subfertility. In late pregnancy she developed pre-eclamptic toxaemia. The baby presented by the breech with legs crossed and deep within the mother's pelvis (Fig 1). There was little amniotic fluid. Three attempts to turn the presentation by external cephalic version failed. Labour commenced at thirty-eight weeks gestation. Surprisingly the baby was born normally by the vertex, having spontaneously turned during labour.

The baby boy, weighing 6lb, had a number of congenital postural deformities: his face appeared squashed, he had a dislocated left hip (CDH) and bilateral talipes equino-varus (Fig 2). There were no malformations.

The congenital dislocation of the left hip (Grade 3) with false acetabulum was confirmed radiologically on the first day of life (Fig 3). Although referred at once for orthopaedic management, treatment was not instituted for seven months. At this time a second radiograph again confirmed the CDH (Fig 4).

Following surgery, the hip was successfully relocated within the acetabulum (Fig 5). The bilateral clubfeet (photographed on the third day of life) are shown in Fig 6 and Fig 7, both in the position of comfort and uncrossed. Note the pressure atrophy over the outer malleoli of both feet where they have been in contact with the mother's pelvic birth canal.

Fig 1. Abdominal x-ray at 35 weeks gestation. The fetus presents by the breech. The head is actutely flexed and the feet are tightly crossed within the mother's pelvis (with parental permission).

Fig 2. Baby following delivery at 38 weeks gestation, with squashed facies and cross-legged position of comfort (day 1).

West of England Medical Journal

Formerly Bristol Medico-Chirurgical Journal

The e-journal of the
Bristol Medico-Chirurgical Society

WEMJ Volume 115 No.3 Article 3 September 2016

Congenital postural deformities of the lower limbs: a case history

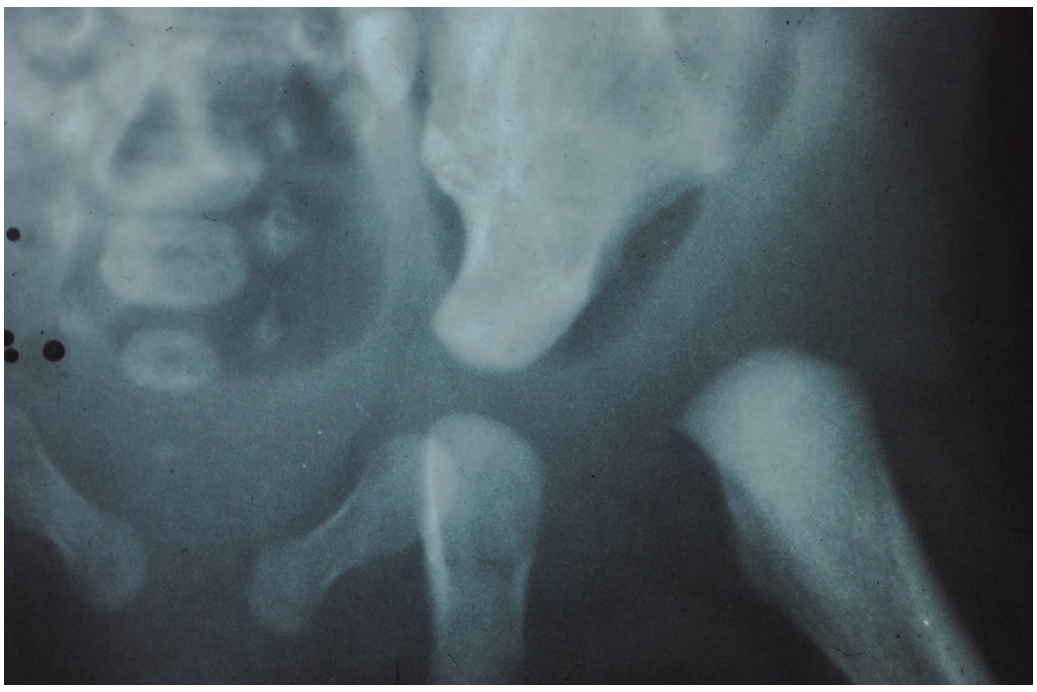

Fig 3. X-ray of left hip on day 1 using von Rosen technique (1) to show full dislocation with false acetabulum.

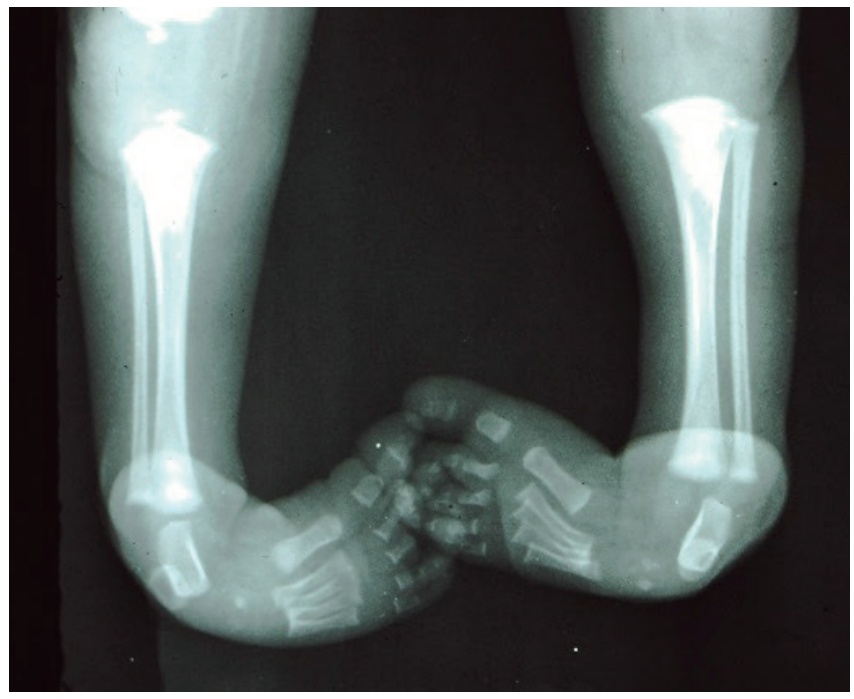

Fig 6
X-ray of lower legs on day 3 showing bilateral club feet.

Fig 4. X-ray of left hip at 7 months demonstrating CDH before treatment.

Fig 7. (a) Bilateral club feet (day 3).

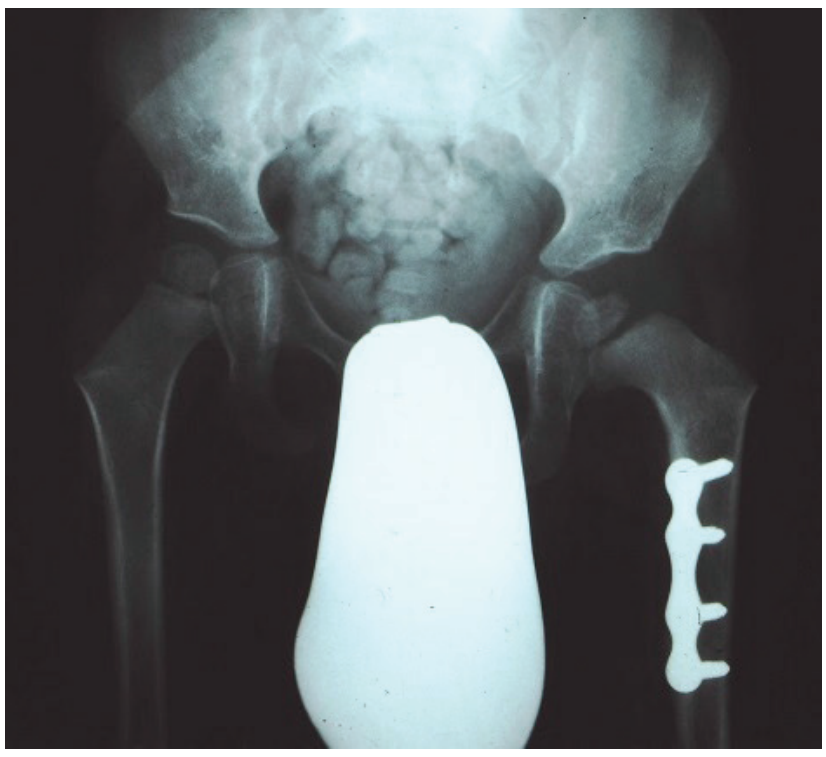

Fig 5.
X-ray of left hip at 4 years following surgery for CDH.

Fig 7(b). Club feet crossed, exhibiting the pressure atrophy over the outer malleoli

West of England Medical Journal

Formerly Bristol Medico-Chirurgical Journal

The e-journal of the
Bristol Medico-Chirurgical Society

WEMJ Volume 115 No.3 Article 3 September 2016

Congenital postural deformities of the lower limbs: a case history

COMMENTARY

Congenital postural deformities affecting the musculo-skeletal system usually arise in late pregnancy as the fetus grows, the volume of amniotic fluid diminishes and the baby becomes constrained and moulded by extrinsic forces within the uterus.

Some 2% of all newborn infants exhibit signs of deformation at birth, though most deformities are mild and resolve spontaneously. Risk factors include first pregnancies because of the tight unstretched maternal abdominal wall, oligohydramnios because normally the amniotic fluid protects the fetus from external pressure and allows it to move, and breech presentation because the fetal legs may be trapped within the mother's pelvis and hence unable to kick and change the baby's position.

The two most common ways in which the legs may be trapped are either with extended knees as in the frank breech presentation or with legs crossed at the ankles. Both positions are well known to, and used by wrestlers. All these 'risk' factors were present in the pregnancy described above [2-4].

Club feet or talipes equino-varus are caused by the sustained cross-legged position in utero. Typically the crossing occurs at the ankle with both feet involved. Sometimes the outer foot provides some protection to the inner one that may be less deformed or spared. The presence of skin dimpling and pressure atrophy over the external malleoli (as in the present case), provides further evicence of prenatal pressure. Browne wrote extensively about this deformity[5,6]. Among his many pertinent observations he stated that CDH did not occur in infants with club feet. He argued that when the fetus had cross-legs, the thighs would be thrown into abduction making the hip joints more stable and less likely to dislocate. While correct in principle, the present case reveals that it may not always be true. Indeed the author has encountered two other similar cases over a period of thirty years. The present case is also of interest as in 1961 when he was born, some authorities were arguing that congenital dislocation of the hip was a misnomer as the condition was not present at birth and that instead it should be renamed infantile dislocation of the hip [7].

REFERENCES

1. Rosen, S. von. Diagnosis and treatment of congenital dislocation of the hip joint in the newborn. J. Bone Joint Surg., 1962, 44-B, 284.
2. Dunn, P.M. The influence of the intrauterine environment in the causation of congenital postural deformities, with special reference to congenital dislocation of the hip. University of Cambridge, MD thesis, 1968.
3. Dunn, P.M. Congenital postural deformities. Brit. Med. Bull., 1976; 32, 71-76.
4. Dunn, P.M. On the pathogenesis of club foot. Lancet, 1985; 1, 635.
5. Browne, D. Talipes equino-varus. Lancet, 1934; 2, 969.
6. Browne, D. Congenital deformities of mechanical origen. Arch. Dis. Childh., 1955; 30, 37-41.
7. Caffey, J., Ames, R., Silverman, W.A., Ryder, C.T. and Hough, G. Pediatrics, 1956; 17, 632.